

Original article

A single-center prospective pilot open-label study to assess the efficacy of topical application of an oxygen-enriched oil for the treatment of angular cheilitis

Paolo G. Arduino¹⁾, Marco Cabras¹⁾, Alessandra Macciotta²⁾, Francesca Longhi¹⁾, Alessio Gambino¹⁾, and Roberto Broccoletti¹⁾¹⁾ Department of Surgical Sciences, University of Turin, Turin, Italy.²⁾ Department of Clinical and Biological Sciences, University of Turin, Turin, Italy

(Received October 1, 2021; Accepted December 14, 2021)

Abstract

Purpose: The aim of this pilot study was to clarify the acceptability and clinical efficacy of an oxygen-enriched oil-based gel for treatment of angular cheilitis.

Methods: A class IIb medical preparation, packaged in appropriate syringes, was tested. Patients were instructed how to use the gel for 10 days: finger rub application (3 times daily) on the dried lesion after meals, without eating, drinking, or speaking for at least 30 min thereafter. The Wilcoxon signed-rank test was used to assess whether there were any differences in the distributions of reported pain and lesion dimension. A microbiological examination was also performed with oral swabs; chi-squared test was used to compare the difference in the presence of microorganisms before and after treatment.

Results: Thirty patients were treated. A significant improvement in reported outcome and a significant reduction in the initially measured largest dimension of the lesion were observed after use of the clinical protocol. Additionally, a significant reduction in the pathogen count was found.

Conclusion: Even if with limitations, data showed that this medical preparation facilitated prompt recovery from reported pain, without adverse reactions. Further work with a larger study population, and possibly a randomized control medication, will be needed.

Keywords: angular cheilitis, hyper-oxidized oil, microbiology, treatment

Introduction

Angular cheilitis (AC) was first described in 1855 by Lemaistre using the term “perlèche”, from the French word “pourelécher” (to lick one’s lips), being characterized by aphthous ulcers at the corners of the lips, prompting patients – mainly children – to “lick their lips at any time.” AC is a common condition, especially in the elderly, and it is the term most commonly used in the literature, suggesting inflammation (suffix: “-i” is”) at the corners (angles) of the lips (Greek term cheilos) [1,2]. It is clinically characterized by erythema, rhagades, ulcers and crusting on the lip corners and adjacent skin, in either one or two commissures [1]. *Candida albicans* and *Staphylococcus aureus* are the two most frequently linked microorganisms [3-6], although few microbiological studies have been conducted to date. AC has various possible etiologies, including systemic causes such as nutritional deficiency [7], xerostomia [2,8], genetic disorders [4], autoimmune bullous diseases [9], orofacial granulomatosis [10] and Crohn’s disease [11,12]. However, local factors are usually responsible for most of the reported cases. These may include insufficient or inappropriate support of the lip corners, salivary stasis, and maceration of the commissures (mainly due to a reduced vertical occlusal dimension resulting from edentulism or ill-fitting dentures, weight loss, malnutrition, smoking,

and mouth breathing) [1]. Although antifungals have been reported as a first-line treatment, very limited scientific evidence has supported their reliability; alternative topical treatments, various techniques for occlusal vertical dimension restoration, B-vitamin supplementation, anti-drooling prostheses and photodynamic therapy have also been rarely tested, and the results have been conflicting [1].

Currently, oxygen is considered to be a necessary component among the distinctive factors affecting the tissue repair process; it has also been proved to have an antimicrobial effect, acting specifically on anaerobes and pyogenic bacteria [13,14]. By exploiting their ability to store oxygen and ozone (O₃) in an olive oil matrix, therapeutic gels that can modulate the response of injured tissue have been developed in recent years. Olive oil is one of the best reservoirs of ozone due to its ability to stabilize it between the double bonds of unsaturated fatty acids. In this setting, ozone has been used successfully as a healing promoter for diabetic ulcer, trophic and ischemic ulcer, and other types of chronic lesion [13]. Moreover, recently, an oxygen-enriched oil has been tested for its ability to facilitate the healing process (by creating a local microenvironment favorable for activation of the microcirculation and unfavorable for the proliferation of pathogens) through the release of reactive oxygen species (ROS) and, due to its oily nature, acting as a protective barrier with a lenitive effect [15,16].

Based on these earlier findings, the aim of this single-center prospective open-label study was to investigate the tolerability and potential clinical efficacy of an oxygen-enriched oil-based gel (a class IIb medical preparation) with a film-forming and protective function, in patients affected by AC.

Materials and Methods

Study population

The study was approved by the Ethical Board of CIR-Dental School, University of Turin, and registered in the ISRCTN registry (#26092754).

Subjects presenting with clinical signs of AC, lasting for at least 8 weeks and requiring treatment, were recruited among patients attending the Oral Medicine Unit of the University of Turin (Italy). The clinical diagnosis was confirmed by an experienced oral physician (PGA).

A prospective case series (between August 2018 and November 2020) was planned (Table 1). All eligible candidates were informed about the experimental protocol and different treatment options were discussed; they submitted written informed consent, in compliance with the declaration of Helsinki. The inclusion criteria were a) age ≥18 years; b) no other detectable oral mucosal lesions; c) reduced vertical dimension caused by edentulism (partial of total) or ill-fitting dentures. Exclusion criteria were a) current history of topical treatment for the reported lesion in the previous 3 weeks; b) inability or reluctance to provide informed consent; c) noteworthy psychiatric or cognitive impairment; d) pregnant or breast-feeding women; e) noteworthy medical history (e.g., systemic infective disease, heart and vascular disease, liver disease, hematological disease, coagulation deficiency, uncontrolled diabetes, and previous or current neoplastic disease); f) patients receiving treatment with paroxetine, tetracyclines, or metronidazole.

A healthy control sample group, with no evident labial lesions, was also recruited from patients attending two different dental private practices (Turin, Italy) to identify microbiological differences from the case group

Correspondence to Dr. Paolo G. Arduino, Department of Surgical Sciences, Oral Medicine Section, University of Turin, CIR-Dental School, Via Nizza 230, 10126 Turin, Italy
Fax: +39-11618639 E-mail: paologiacomo.arduino@unito.it

Color figures can be viewed in the online issue at J-STAGE.
doi.org/10.2334/josnusd.21-0428
DN/JST.JSTAGE/josnusd/21-0428

Table 1 The clinical protocol employed

Time 0 _Day 0 (T0):
- Clinical evaluation
- Evaluation of the dimension of the lesion
- VAS record
- Oral swab
- Start with Novox (3 times daily, 10 minutes after oral home hygiene procedures)
Time 1 _Day 10 (T1):
- Clinical evaluation
- Evaluation of the dimension of the treated lesion
- VAS record
- Oral swab
- Stop with Novox

at the baseline (Table 2). The clinical pictures of all healthy patients were studied by an expert oral physician (PGA) to confirm the absence of AC.

Clinical sampling protocol

Microbiological samples were taken using individually wrapped sterile cotton swabs (each moistened with 1 drop of sterile distilled water) mounted on a plastic stick (Meus S.r.l., Piove di Sacco, Italy), previously stored at room temperature. Each swab was rubbed once across one commissure of the mouth for 20 s. After the sample had been taken, each swab was placed in a polypropylene test tube containing 3.0 mL of Stuart transport medium (Remel, Lenexa, KS, USA). These tubes were stored at 4°C until processing (never more than 72 h).

Microbiological evaluation

The biological material was dissolved in 0.9% NaCl solution, and a 100-mL aliquot was then plated on agar in a 10-cm Petri dish. Three types of agar were used: a) blood agar to isolate and detect hemolytic activity, b) McConkey agar for identification of gram-negative bacteria, and c) mannitol salt agar to identify organisms that ferment mannitol. All of the Petri plates were incubated for 24 h at 37°C in a microbiological incubator. If colony growth on the different agar plates was evident, the next step was preparation of a suspension for identification of single bacteria. Sufficient colonies from the culture were picked up with a sterile swab stick and suspended in 3.0 mL of sterile saline (aqueous 0.45-0.50% NaCl, pH 4.5-7.0) in a plastic polystyrene test tube; the turbidity was adjusted and measured using Vitek Densicheck (Biomérieux Italia S.p.A., Bagno a Ripoli, Florence, Italy).

Four reagent cards were used for the identification of different pathogenic organism classes: GN for gram-negative fermenting and non-fermenting bacilli, GP for gram-positive cocci, and non-spore-forming bacilli, YST for yeasts and yeast-like organisms, and BCL for gram-positive spore-forming bacilli.

The identification cards were inoculated with the microorganism suspensions using an integrated vacuum apparatus and processed according to the Vitek 2 protocol (Biomérieux Italia S.p.A.). The Vitek 2 Compact system (30 card capacity) uses a fluorogenic methodology for organism identification and a turbidimetric method for susceptibility testing using a 64-well card that is barcoded with information on card type, expiration date, lot number and a unique card identification number. Test kits available include ID-GN (gram-negative bacillus identification), ID-GP (gram-positive coccus identification), AST-GN (gram-negative susceptibility) and AST-GP (gram-positive susceptibility). The Vitek 2 ID-GN card identifies 154 species of Enterobacteriaceae and a select group of glucose non-fermenting gram-negative organisms within 10 h. The Vitek 2 ID-GP card identifies 124 species of staphylococci, streptococci, enterococci, and a select group of gram-positive organisms within 8 h or less. The Vitek 2 antimicrobial susceptibility test (AST) is for most clinically significant aerobic gram-negative bacilli, i.e. *Staphylococcus* spp., *Enterococcus* spp. and *Streptococcus agalactiae*. Susceptibility results are available for bacteria in less than 18 h.

The “Test Card Setup Procedure” was as follows:

1. Prepare inocula from a pure culture, according to good laboratory practice. For of a mixed culture, an isolation step is required. A purity check plate is recommended to ensure that a pure culture was used for testing.
2. Aseptically transfer 3.0 mL of sterile saline (0.45-0.5% NaCl, pH 4.5-7.0) into a clear plastic (polystyrene) test tube (12 mm × 75 mm).
3. Use a sterile stick or swab to transfer a sufficient number of morpho-

logically similar colonies to the saline tube prepared in step 2. Prepare a homogeneous organism suspension with a density equivalent to the appropriate McFarland standard using Vitek 2 DensiCHEK Plus.µL

4. In a second tube containing 3.0 mL of saline, transfer 145 µL of the suspension prepared in step 3 for AST-GN cards or 280 µL of the suspension prepared in step 3 for AST-GP cards. Then place this tube in the cassette with a susceptibility card. The tube with the initial bacterial suspension can also be used for inoculation of an identification card.

Calculation and identification were performed using raw data and compared to the threshold values to determine the reactions for each test. For Vitek 2 Compact, the test reaction results appeared as “+”, “-”, “(-)” or “(+)”.

Valuation of pain and clinical involvement

Pain perception was assessed using a visual analogue scale (VAS) consisting of a 10-cm horizontal line with ten equally spaced marks representing a range of pain from 0 (no pain) to 10 (most severe pain possible). The largest dimension of each lesion was marked and measured by a single operator (PGA) using a periodontal probe (1-15 mm).

Treatment provided

An oxygen-enriched oil-based medical preparation (NovoX-Drop, MOSS S.p.A, Lesa, Italy) was used, packaged in apposite syringes by the manufacturer. The medication remains a gel if stored at a temperature lower than 26°C, and if it becomes fluid, it can revert to its optimal physical state without any alteration of quality once refrigerated (<8°C) for a brief period. The preparation was applied 3 times daily for 10 days. All patients were carefully instructed how to apply it: rubbing with a finger onto the dried lesion after meals, and then refraining from eating, drinking or speaking for at least half an hour afterwards.

Outcome measures

Clinical evaluations and oral swab sampling were conducted at the baseline (t0), when the treatment was started, and at 10 days (t1) after the end of the treatment period. The primary outcome of the study was the change in spontaneous pain intensity (assessed using the VAS scale) at t1.

Changes in the largest dimension of the lesion and in microbiological flora were considered as secondary outcomes.

The patients were also provided with a diary to record any possible unexpected effects of the treatment.

Statistical analysis

The number of cases was not estimated based on the absence of any previously reported data for this type of therapy in patients with AC. Otherwise, with regard to possible microbiological differences between cases and controls, the sample size was calculated according to available data suggesting an overall presence of infection of 80% and 35% for affected and non-affected subjects, respectively. For a power of 92% and a type I error of 0.05, 60 patients (30 for each arm) were needed.

First, the Shapiro-Wilk test was used to examine any non-normal distribution of the continuous variables. Then, Fisher’s exact test and the Wilcoxon-Mann-Whitney test were used to examine equivalence between the two groups, according to the distributions of the considered variables (age, sex, and smoking habits). A descriptive analysis was performed on patients’ characteristics and outcomes: continuous variables were expressed as median and interquartile range, and categorical variables as frequencies and percentages. The chi-squared test was used to compare differences in the presence of microorganisms at t0 and t1, while the Wilcoxon signed-rank test was used to assess whether there were any differences between t0 and t1 in the distributions of VAS and the largest dimension measured. Analyses were performed using R software (version 4.0.2) considering a first type error of $\alpha = 0.05$.

Results

A total of 60 patients were evaluated, 39 of whom were female (f/m = 1.86/1). Table 2 shows the principal characteristics of the two study groups, who were similar in terms of smoking status, age, and gender.

AC was due to a reduced vertical dimension caused by edentulism in 20 patients, and by ill-fitting dentures in the remaining 10. The average

Table 2 Main features of the cases and controls

		Cases N° 30	Controls N° 30	P
Age (median [IQR])		66.00 (57.00, 79.75)	64.00 (44.00, 77.00)	0.610 ^e
Gender	male	9 (30.0%)	12 (40.0%)	0.417 [§]
	female	21 (70.0%)	18 (60.0%)	
Smoking status	yes	4 (13.3%)	3 (10.0%)	1.000 [#]
	no	26 (86.7%)	27 (90.0%)	
Microbiological evaluation*	negative	0 (0.0%)	26 (86.7%)	<0.001 [#]
	1	8 (26.7%)	2 (6.7%)	
	2	14 (46.7%)	1 (3.3%)	
	3	4 (13.3%)	1 (3.3%)	
	4	1 (3.3%)	0 (0.0%)	
	5	1 (3.3%)	0 (0.0%)	
	6	2 (6.7%)	0 (0.0%)	
Presence of pathogens	yes	30 (100%)	4 (13.3%)	<0.001 [#]
	no	0 (0.0%)	26 (86.7%)	
Individual disease duration weeks		18.00 [7.00, 27.00]	-	-

*1 = presence of *Staphylococcus aureus*; 2 = presence of *Candida albicans*; 3 = presence of *Staphylococcus aureus* and *Candida albicans*; 4 = presence of *Escherichia coli*; 5 = presence of *Enterobacter aerogenes*; 6 = presence of *Candida albicans* and *Escherichia coli*. ^eWilcoxon signed rank test; [§]Chi-squared test; [#]Fisher's exact test

Table 3 Comparison of parameters examined before (t0) and soon after (t1) application of the treatment protocol

		Cases N° 30 Baseline (t0)	After treatment (t1)	P
Primary outcome				
VAS (median [IQR])		3.00 (2.00, 5.00)	0.00 (0.00, 1.00)	<0.0001 ^e
Secondary outcomes				
Lesion size (median [IQR])		5.00 (3.25, 7.00)	0.00 (0.00, 2.00)	<0.0001 ^e
Microbiological evaluation*	negative	0 (0.0%)	25 (83.3%)	<0.001 [§]
	1	8 (26.7%)	2 (6.7%)	
	2	14 (46.7%)	0 (0.0%)	
	3	4 (13.3%)	3 (9.9%)	
	4	1 (3.3%)	0 (0.0%)	
	5	1 (3.3%)	0 (0.0%)	
	6	2 (6.7%)	0 (0.0%)	
Presence of pathogens	yes	30 (100%)	5 (16.7%)	<0.001 [§]
	no	0 (0.0%)	26 (83.3%)	

*1 = presence of *Staphylococcus aureus*; 2 = presence of *Candida albicans*; 3 = presence of *Staphylococcus aureus* and *Candida albicans*; 4 = presence of *Escherichia coli*; 5 = presence of *Enterobacter aerogenes*; 6 = presence of *Candida albicans* and *Escherichia coli*. ^eWilcoxon signed rank test; [§]Chi-squared test

reported duration of the problem was about 18 weeks (Table 2).

Regarding the initial identification of possible involved pathogens, the results of microbiological evaluation differed significantly between the groups. In the group without clinical signs of AC, only four subjects (13.3%) were positive for *Staphylococcus aureus*. In contrast, many different species were identified in the patients with clinical signs of AC: *Staphylococcus aureus* in 8 cases (26.7%), *Candida albicans* in 14 (46.7%), *Escherichia coli* and *Enterobacter aerogenes* in 1 (3.3%). Moreover, in some cases, more than 1 species was present: 4 cases (13.3%) with *Staphylococcus aureus* and *Candida albicans*, and 2 (6.7%) with *Candida albicans* and *Escherichia coli*.

Table 3 shows a comparison of parameters examined before and soon after application of the treatment protocol. A significant reduction in the total count of pathogens at the site of infection was observed ($P < 0.01$). Above all, there was a significant reduction in the reported outcome of patients, in terms of the VAS score (Figs. 1, 2). There was also a reduction in lesion dimension after application of the clinical protocol (Figs. 1, 2).

No patient complained about undesirable side effects. Even though all patients were initially (t0) informed of the unpleasant taste of the preparation, only 10% of them still complained about it at t1.

Discussion

The clinical effectiveness of an oxygen-enriched oil-based gel in patients affected by AC has never been documented. Despite a number of limitations, particularly the limited number of patients and the absence of a control group, our present study indicated that this preparation could reduce pain and the dimensions of the AC lesions.

To date, it has been unclear which treatment would be most reliable for routine clinical management of AC [2], a disease basically caused by infection with *Candida albicans* (65%) and *Staphylococcus aureus* (30%) (Table 2) [2]. Based on our previous experience, topical management with antifungals combined with corticosteroids appeared to be a reliable

approach, but this could lead to some adverse events, especially in elderly patients [2]. In recent years, the appropriateness of unconventional and non-pharmacological therapy for AC has been receiving greater clinical and research interest. This has led to the testing of new compounds that can be readily prescribed especially for the elderly, who sometimes show poor compliance with traditional steroid medication [1,2].

The main component (98% w/w) of NovoX-Drop is oxygen-enriched extra-virgin olive oil. The patented oxygen enrichment process is based on exposure of the oil matrix to an ozone-oxygen mixture, allowing oxygen to become chemically bound to the fatty acid chains. Upon interaction with lesion tissue and fluids, these bonds are progressively broken, allowing oxygen to be released in the form of ROS; this induces a change in the local lesion microenvironment, at the same time favoring the wound healing process and hindering the proliferation of pathogens. Among the various factors that can affect the complex tissue repair process, oxygen is widely considered a key element with proven bacteriostatic and bactericidal actions [13]. The likely mechanism by which oxygen-enriched oil-based formulations act on a wide range of pathogens is oxidation through the slow release of ROS; application of oxygen-release formulations can increase the lesion oxygen content, especially in cases where it is either totally lacking or deficient due to increased local metabolism [17,18]. Among the primary causes of lesion repair failure, inflammation appears to be the main culprit, and the redox system, which produces ROS, plays a key role in maintaining an inflammatory state, dynamically influencing metabolic and environmental signaling responses at the cellular level [19]. ROS, together with nitrogen species, carbon monoxide and hydrogen sulfite metabolites, play an important autocrine and paracrine role in cellular signaling. Various signals from the cellular microenvironment regulate the biosynthesis and catabolism of these mediators via mitochondria, nitric oxide synthase, heme oxygenase, oxidase, peroxidase, superoxide dismutase, cystathionine b-synthase and cystathionine c-lyase. Activation of these signaling molecules is controlled by the transduction pathway (activated by binding of secreted factors to cell membrane receptors) and the mechanotransduction pathway (induced

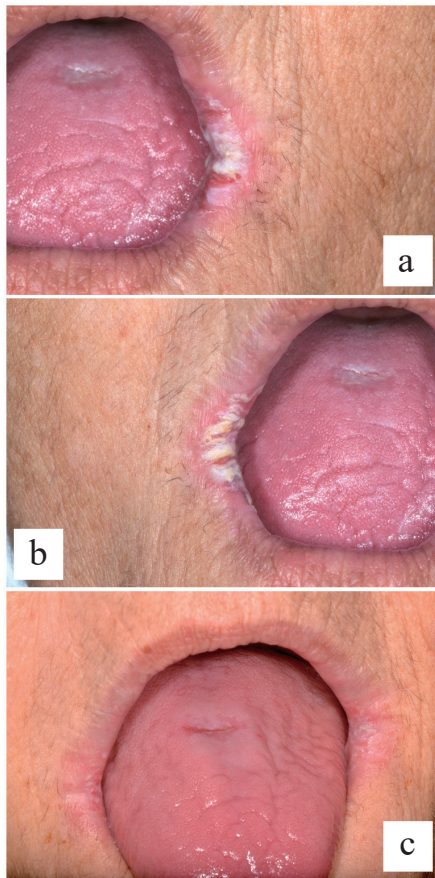


Fig. 1 Signs of bilateral AC before (a, b) and after (b) the proposed protocol (pt #11)

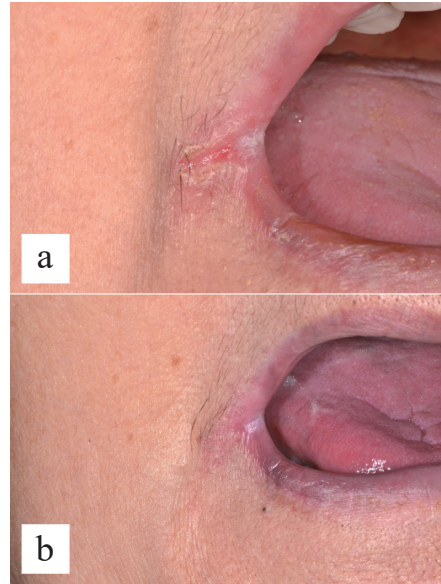


Fig. 2 Signs of right AC before (a) and after (b) the proposed protocol (pt #28)

by changes in the rigidity of the extracellular matrix), which acts as an anchor for most cells, playing a key role in response to injury and stress) [17,19]. These molecules differ from structural proteins such as integrins, and bind transiently to specific receptors for intracellular signaling, including thrombospondin 1, to regulate tissue perfusion [20]. Largely, it can be said that the redox system also plays a role in repair of the extracellular matrix in diseases such as diabetes, either directly or via cell signaling [21-23]. ROS are central to many biological processes and their production appears to be regulated by a mechanism mediated by high and low intracellular concentrations.

This aim of the present study was to evaluate whether application of an oxygen-enriched oil-based gel would influence the clinical course of patients with AC. Analysis of the clinical parameters revealed that the preparation significantly reduced the degree of reported pain and the dimension of the lesions. No patient complained about the mode of administration, and the syringe formulation was easy to use on the lips, with a high degree of tolerability and without any adverse effects.

The results of this preliminary evaluation suggest that application of an oxygen-enriched ointment may represent a practical treatment for pain reduction in AC, as well as favoring the healing process. The study has provided descriptive data for assessing the safety and tolerability of the evaluated treatment, with encouraging results and no apparent adverse effects.

Although it is not possible to draw definitive conclusions in view of the small sample size, these results may pave the way for future investigations. Further work with larger study populations, and possibly a control medication, conducted in a randomized manner, will be needed to verify these initial results.

Acknowledgments

The authors are grateful to MOSS S.p.A. (Lesa, Italy) for free provision of the products investigated and coverage of the publication fees.

Conflict of interest

All of the authors declare that they have no conflicts of interest related to

this study.

References

- Pilati S, Bianco BC, Vieira D, Modolo F (2017) Histopathologic features in actinic cheilitis by the comparison of grading dysplasia systems. *Oral Dis* 23, 219-224.
- Cabras M, Gambino A, Broccoletti R, Lodi G, Arduino PG (2019) Treatment of angular cheilitis: a narrative review and authors' clinical experience. *Oral Dis*, Aug 29, doi: 10.1111/odi.13183.
- Warnakulasuriya KA, Samaranyake LP, Peiris JS (1991) Angular cheilitis in a group of Sri Lankan adults: a clinical and microbiologic study. *J Oral Pathol Med* 20, 172-175.
- Manfredi M, Polonelli L, Aguirre-Urizar JM, Carozzo M, McCullough MJ (2013) Urban legends series: oral candidosis. *Oral Dis* 19, 245-261.
- Oza N, Doshi JJ (2017) Angular cheilitis: a clinical and microbial study. *Indian J Dent Res* 28, 661-665.
- Hellstein JW, Marek CL (2019) Candidiasis: red and white manifestations in the oral cavity. *Head Neck Pathol* 13, 25-32.
- Kaur S, Goraya JS (2018) Dermatologic findings of vitamin B12 deficiency in infants. *Pediatr Dermatol* 35, 796-799.
- Gambino A, Broccoletti R, Cafaro A, Cabras M, Carcieri P, Arduino PG (2017) Impact of a sodium carbonate spray combined with professional oral hygiene procedures in patients with Sjögren's syndrome: an explorative study. *Gerodontology* 34, 208-214.
- Caetano Lde V, Enokihara MM, Porro AM (2015) Recurrent angular cheilitis in a patient with mucocutaneous pemphigus vulgaris. *Clin Exp Dermatol* 40, 819-821.
- McCartan BE, Healy CM, McCreary CE, Flint SR, Rogers S, Toner ME (2011) Characteristics of patients with orofacial granulomatosis. *Oral Dis* 17, 696-704.
- Bangsgaard N, Weile B, Skov L (2011) Organised angular cheilitis as the initial sign of Crohn's disease in two children. *Acta Derm Venereol* 91, 207-208.
- Howell JL, Bussell RM, Hegarty AM, Zaitoun H (2012) Service evaluation of patients with orofacial granulomatosis and patients with oral Crohn's disease attending a paediatric oral medicine clinic. *Eur Arch Paediatr Dent* 13, 191-196.
- Sen CK, Khanna S, Gordillo G, Bagchi D, Bagchi M, Roy S (2002) Oxygen, oxidants and antioxidants in wound healing: an emerging paradigm. *Ann N Y Acad Sci* 957, 239-249.
- Cassino R, Ippolito AM, Cuffaro P, Corsi A, Forma O (2015) Evaluation of the effectiveness of a hyperoxidized oil-based medication in the treatment of skin lesions: observational study. *Minerva Chir* 70, 23-31.
- Lauret S, Aborajoo H, Mattioli B, Poggioli G (2016) Treatment of minor dehiscence after endorectal advancement flap in perianal Crohn's fistulas with ozonized oil NOVOX. *Tech Coloproctol* 20, 139-140.
- Anzolin AP, da Silveira-Kaross NL, Bertolo CD (2020) Ozonated oil in wound healing: what has already been proven? *Med Gas Res* 10, 54-59.
- Montevocchi M, Dorigo A, Cricca M, Checchi L (2013) Comparison of the antibacterial activity of an ozonated oil with chlorhexidine digluconate and povidone-iodine. A disk diffusion test. *New Microbiol* 36, 289-302.
- Kumar T, Arora N, Puri G, Aravinda K, Dixit A, Jatti D (2016) Efficacy of ozonized olive oil in the management of oral lesions and conditions: a clinical trial. *Contemp Clin Dent* 7, 51-54.
- Jakubczyk K, Dec K, Kalduńska J, Kawezuga D, Kochman J, Janda K (2020) Reactive oxygen species - sources, functions, oxidative damage. *Pol Merkur Lekarski* 48, 124-127.
- Befekadu R, Christiansen K, Larsson A, Grenegård M (2019) Increased plasma cathepsin S and thrombospondin-1 in patients with acute ST-segment elevation myocardial infarction. *Cardiol J* 26, 385-393.
- Kunkemoeller B, Kyriakides TR (2017) Redox signaling in diabetic wound healing regulates extracellular matrix deposition. *Antioxid Redox Signal* 27, 823-838.
- Roberts DD (2017) Extracellular matrix and redox signaling in cellular responses to stress. *Antioxid Redox Signal* 27, 771-773.
- Roberts DD, Kaur S, Isenberg JS (2017) Regulation of cellular redox signaling by matrix proteins in vascular biology, immunology, and cancer. *Antioxid Redox Signal* 27, 874-911.